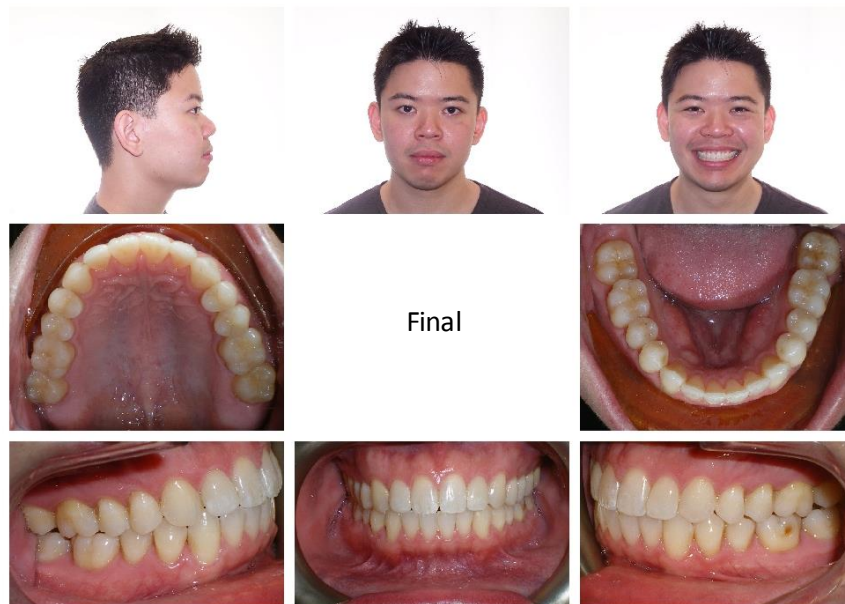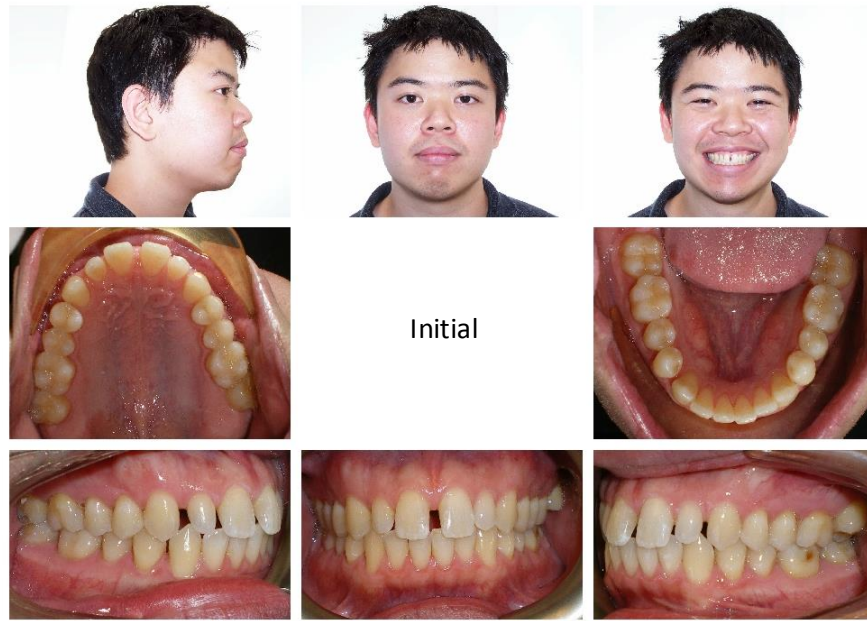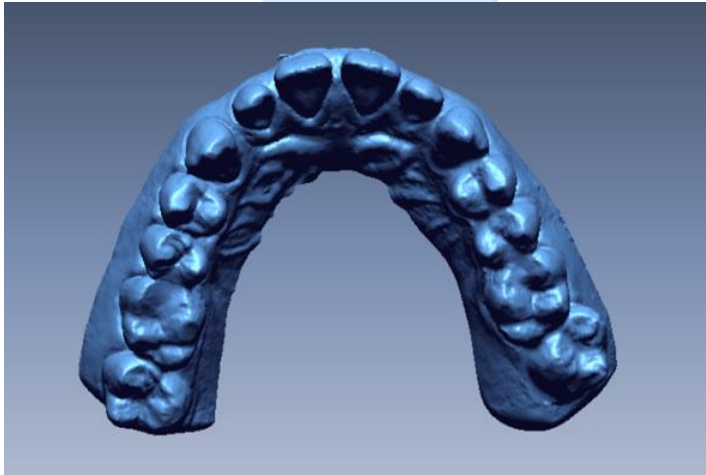
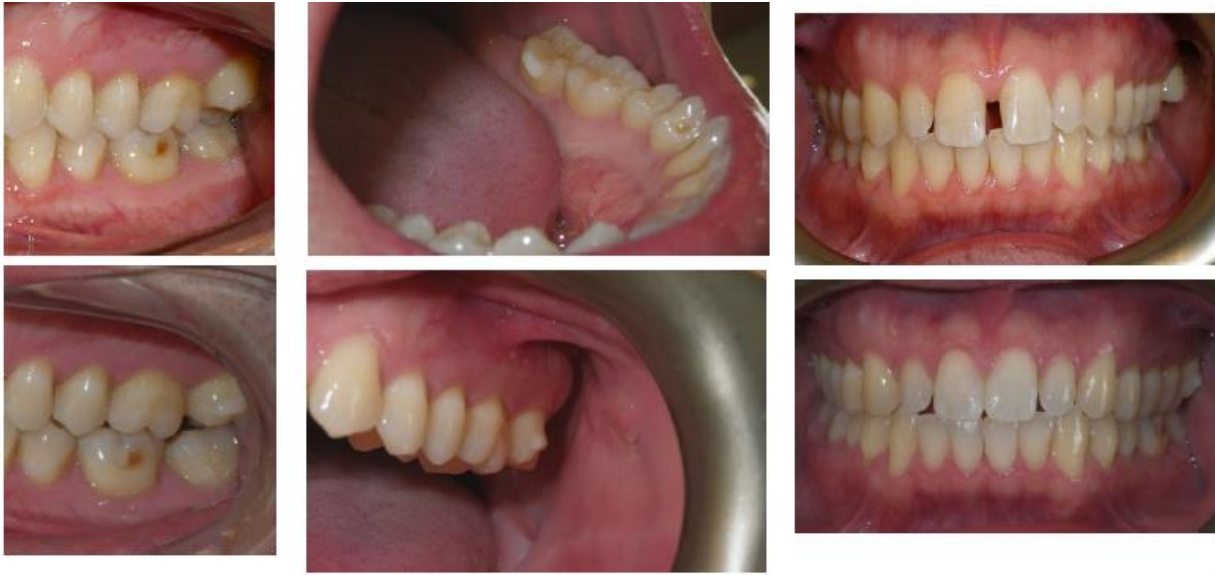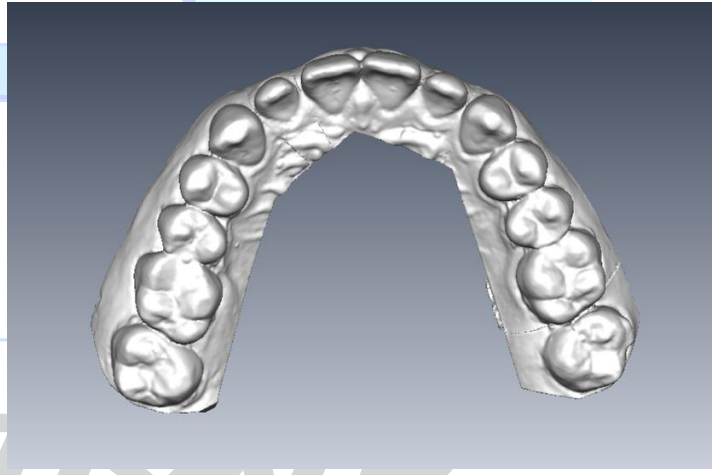


Multidisciplinary restorative orthodontic treatment. Upper and lower space closure, alignment and positioning of incisors to optimize esthetic dental care. Maxillary left second molar in buccal crossbite. Buccal and lingual attachments placed with Reliance Flow Tain (flowable light cure composite) on upper and lower left second molars prior to scan to enhance tooth movement.





Initial



Final/Before Restorations

*o d o n t i c T*