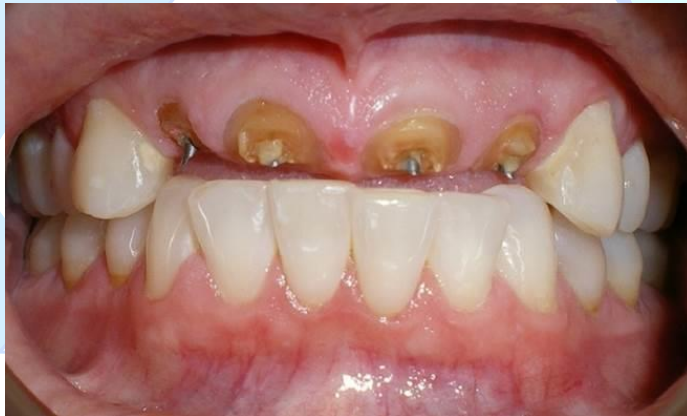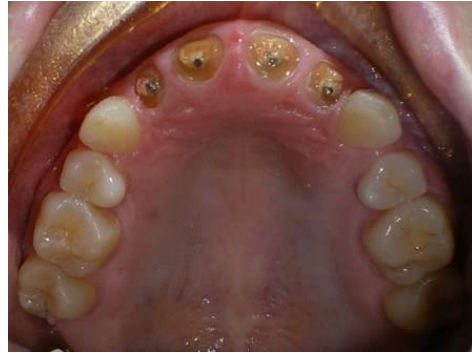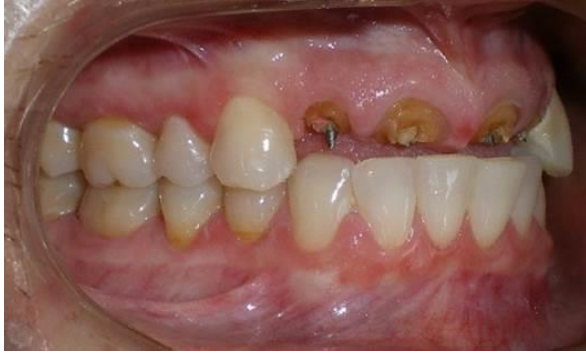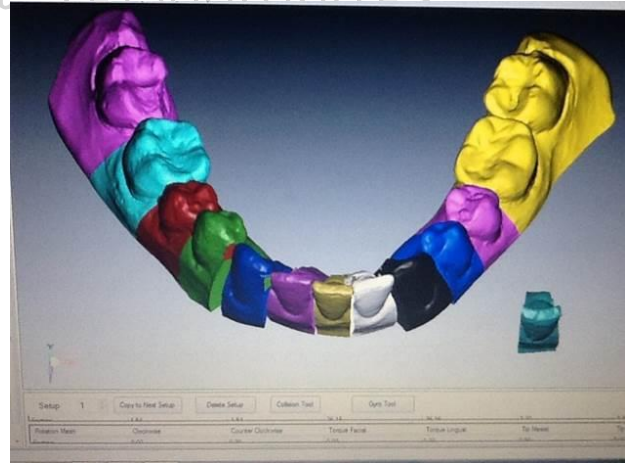
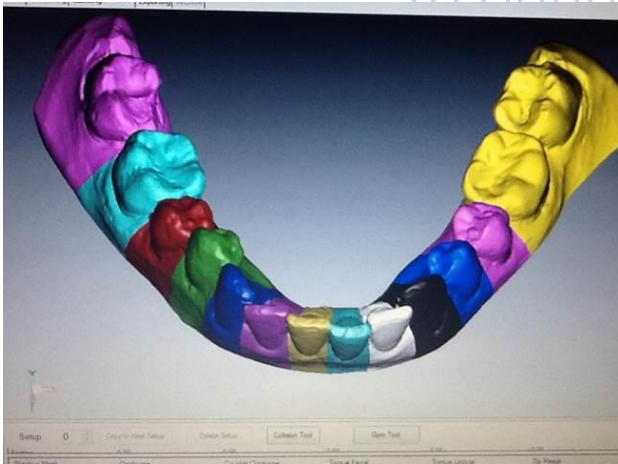


Patient presents with failed anterior restoration. Prosthodontist recommending extraction of retained maxillary incisor roots and 4 unit implant supported anterior bridge. Inadequate vertical and horizontal clearance currently for restoration. Diagnostic setup performed to visualize additional clearance for restorative care possible with fixed orthodontic treatment and extraction of a lower left central incisor.



ORCHESTRATE
Orthodontic Technologies





Orchestate3D – Diagnostic Setup